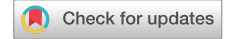

Radiological Characteristics of Renal Lesions During Tuberous Sclerosis Complex: Impact of Mechanistic Target of Rapamycin Inhibitor Treatment



Pierre Pfirmann¹, Eva Jambon², Jérôme Aupy^{3,6}, Jean-christophe Bernhard⁴, Hugo Bakis¹, Christian Combe^{1,5}, Nicolas Grenier² and Claire Rigotherier^{1,5}

¹Centre Hospitalier Universitaire (CHU de) Bordeaux, Service de Néphrologie-Transplantation-Dialyse-Aphérèses, Hôpital Pellegrin, Bordeaux, France; ²CHU de Bordeaux, Service d'Imagerie Médicale, Hôpital Pellegrin, Bordeaux, France; ³CHU de Bordeaux, Département de neurosciences cliniques, Hôpital Pellegrin, Bordeaux, France; ⁴CHU de Bordeaux, Service d'urologie, Hôpital Pellegrin, Bordeaux, France; ⁵Institut National de la Santé et de la Recherche Médicale (INSERM) U1026, BioTis, Université de Bordeaux, Bordeaux, France; and ⁶Centre National de la Recherche Scientifique (CNRS) UMR 5293, IMN, Université de Bordeaux, Bordeaux, France

Correspondence: Pierre Pfirmann, CHU de Bordeaux, Service de Néphrologie-Transplantation-Dialyse-Aphérèses, Hôpital Pellegrin, 2 place Amélie Raba Léon, 33000, Bordeaux, France. E-mail: pierre.pfirmann@chu-bordeaux.fr

Received 25 April 2022; revised 19 July 2022; accepted 21 July 2022; published online 3 August 2022

Kidney Int Rep (2022) 7, 2299–2302; <https://doi.org/10.1016/j.ekir.2022.07.168>

KEYWORDS: angiomyolipoma; computed tomography; genetic disease; mammalian target of rapamycin inhibitor; radiology; tuberous sclerosis complex

© 2022 Published by Elsevier, Inc., on behalf of the International Society of Nephrology. This is an open access article under the CC BY-NC-ND license (<http://creativecommons.org/licenses/by-nc-nd/4.0/>).

INTRODUCTION

Tuberous sclerosis complex (TSC) is an autosomal dominant multisystemic disorder.¹ Pathogenic variants in TSC1 or TSC2 gene lead to hyperactivation of the mammalian target of rapamycin (mTOR) signaling pathway, with a consequent deregulation of cell growth and the development of hamartomas. These tumors are benign, but they can cause life-threatening hemorrhage or organ failure in vital organs, such as the kidney, with angiomyolipoma (AML).¹ AML found in 60% to 80% of patients with TSC are tumors composed of smooth muscle-like cells, adipocyte-like cells, and epithelioid cells. The diagnosis of AML is usually made by imaging techniques.² The pivotal feature for the diagnosis, all imaging modalities included, relies on the presence of fat in the AML lesion.³ The main goals for patients with renal AML are prevention of bleeding and preservation of renal function. mTOR inhibitors (mTORi) have been shown to be effective in patients with AML in TSC.

The aim of our study was to describe the computed tomography (CT) characteristics of TSC renal lesions and to assess the effect of mTORi on the different types of lesions.

RESULTS

Fifty patients with abdominal CT were included (Supplementary Methods), (24 [48%] males, mean age

42.8 ± 16.9 years). Predominant lesions were dental lesions with pits (100%), cutaneous (95%), renal (92%), and neurologic manifestations (90%) (Supplementary Table S1).

Thirty three percent of patients presented an estimated glomerular filtration rate of less than 60 ml/min per 1.73 m². Thirty-five (70%) patients had AMLs, including 55% with a combination of renal cysts and AML. Twenty-four percent of patients with AML required preventive embolization, whereas rescue surgery was performed in only 4 cases of bleeding without possibility of embolization. During the follow-up, any major bleeding was reported (Supplementary Table S2).

Our cohort included 78 AMLs considered suitable for repeated measurements. On nonenhancement CT, 57% of AMLs were fat-rich, 30% were fat-poor isoattenuating and 13% were fat-poor hyperattenuating (Supplementary Methods).⁴

Classification of the AMLs in the 4 subtypes, depending on their fat content, was performed with good distinction between groups (Supplementary Methods, Supplementary Figure S1, Supplementary Tables S3 and S4).

The postcontrast enhancement curves showed a significant increase of Hounsfield Units (HU) (47 ± 10 HU, $P < 0.0001$ [95% confidence interval: -70.8; -22.8]) on the arterial phase followed by a plateau on the nephrographic phase (Supplementary Figure S2 and S3). These enhancement curves were identical for the first

Table 1. Evolution of renal lesions under mTORi

Characteristics	Before mTORi	Under mTORi	Difference (mean±SD)	P value	n
Treatment duration (mo)			42±44		
AML size (mm)	49.8±30.6	41.45±27.5	8±10.5	0.0007	26
AML size (%)	100	84	-14.7±17.0	0.0002	26
Pixel density (HU)	-33.2±54.3	-65.6±48.8	-34.1±36.3	0.0005	20
ROI at noncontrast phase (HU)	-16±47.9	-40.1±51.9	-22.6±20.0	<0.0001	20
ROI at arterial phase (HU)	52.8±70.7	-14.6±67.5	-60.8±42.3	<0.0001	20
ROI at nephrographic phase (HU)	36.1±53.03	-1.65±63.2	-30.9±35.5	0.0002	26
Number of cysts	13	13	0		7
Size of right kidney (mm)	161.4	143.4	-18	0.1460	7
Size of left kidney (mm)	153.0	134.1	-18.9	0.1232	7
Number of aneurysms	1	0	-1		7
AML Type					
Type 1	4	2	-2		26
Type 2	4	1	-3		26
Type 3	6	5	-1		26
Type 4	12	18	6		26

AML, angiomyolipoma; HU, Hounsfield units; mTORi, mammalian target of rapamycin inhibitor.

3 subtypes whereas the type 4 have a lower enhancement with a persistence in the nephrographic phase ($P < 0.05$) (Supplementary Figure S4).

Under treatment with mTORi, we observed a decrease in AML size of 20% ($P = 0.0002$ [95% confidence interval: -7.8; -21.5]) (Table 1). The average duration of treatment was 42 months. We also observed a significant increase of their fat component responsible for a decrease in HU at the 3 acquisition phases (Figure 1a). The mean decrease was 22 ± 20 HU at the noncontrast phase ($P < 0.0001$), 61 ± 42 HU on the arterial phase ($P < 0.0001$), and 31 ± 36 HU on the nephrographic phase ($P = 0.0002$).

We observed a decrease of arterial enhancement of 38.2 ± 34.11 HU ($P < 0.0001$ [95% confidence interval: -54.16; -22.24]) associated with a decrease in the vascular component of AML (Supplementary Figure S5).

In a subgroup analysis, significant decrease of arterial enhancement (-19 HU, $P = 0.0421$) and reduction in size (-10.8 mm, $P = 0.0023$) were observed in type 1, 2, and 3 AMLs whereas type 4 did not present any significant modification (Figure 1 b, c, d, e).

DISCUSSION

Herein, we describe the radiologic characteristics and evolution of AML under mTORi in an adult cohort of patients suffering from TSC.

In our cohort, we described 57% of fat-rich AML, 30% being isoattenuating and 13% hyperattenuating AML on noncontrast CT, perfectly matching with the previous Song's results.⁵

We classified AMLs into 4 subgroups according to their visual percentage of fat. We obtained an identical enhancement in the AML groups, except for type 4

with more than 75% of fat tissue. Han *et al.*⁶ observed that angiomatous components were the main causes of bleeding in symptomatic AMLs and the decrement of tumor size after embolization is related to the important response by angiomatous components.

Therefore, the crucial parameter of the bleeding risk is the enhancement of the AML (i.e., the importance of its vascular component, irrespective of its size or of its percentage of fat). Only the fully fat AMLs were less vascularized without preventing the presence of aneurysm. The enhancement of AMLs at the arterial phase seems pivotal in the screening of AMLs with a potential risk of bleeding.⁷

The main therapeutic goals for patients with renal AML are prevention of bleeding and preservation of renal function. In recent years, mTORi has been recommended to prevent the risk of bleeding by reducing AML size. Under treatment, we observed a slight reduction in AML size. This result was contradictory to previous studies in which a size reduction of 50% was reported in 42% of treated patients. Our population in terms of age, sex, mutation and mTORi dose was similar to previous studies. These studies analyzed a decrease in AML volume but not a reduction of AML diameter in the transverse plan. In our patients, a reduction of 20% of diameter (observed for nonfatty AML) was associated with a volume reduction of 50%, and these results are consistent with Exist-2. We also depicted a slight progression of AML size under treatment, which corresponds with the results of previous studies.⁸

In our study, we noted on noncontrast CT, a decrease in density in all cases of AML and, also for the most hypodense part of the AML. This observation was related to the increase in the fat quota of the AML, which had been recently observed on magnetic

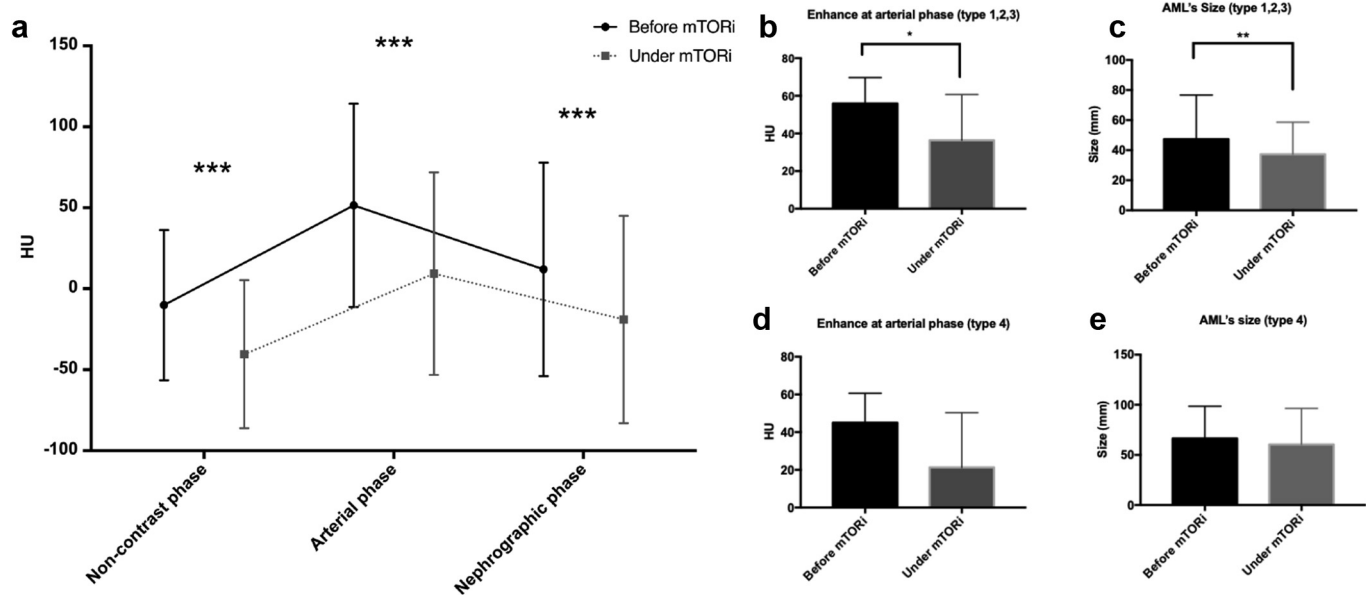


Figure 1. (a) Evolution of AML density with triphasic CT before and under mTOR inhibitor. (b and d) Evolution of the enhancement at the arterial time and (c and e) the size of the AMLs according to the type of AML. HU, Hounsfield units.

resonance imaging and CT.⁷ A decrease in arterial time of enhancement was also noted, related to a decrease in vascularization under mTORi. As reported in the literature, mTORi induced a reduction in circulating vascular endothelial growth factor by their antiangiogenesis effect.^{8,9} In addition to size reduction, mTORi reduce the risk of bleeding AML, and thus help preserving renal function. Nevertheless, we highlighted only a reduction in size and enhancement of AML only for AML type I, II, and III. The mTORi seem to be less effective on very fatty AMLs, which are less vascularized structures.

No bleeding event was observed in our study. Clinical tolerance was similar to the previous studies, with side effects already reported.⁸ We noticed skin improvement in the adult population. No modification of neurological pattern was depicted.

In conclusion, the imaging follow-up after mTORi have to be performed with triphasic acquisition. A slightly reduction of AML size, a decrease of vascularization contingent with an increase of fat component is expected.

DISCLOSURE

All the authors declared no competing interest.

ACKNOWLEDGMENTS

We thank patients and their families. We thank all the TSC day hospitalization team.

SUPPLEMENTARY MATERIAL

Supplementary File (PDF)

Supplementary Methods.

Figure S1. Angiomyolipoma repartition in 4 types

Figure S2. Angiomyolipoma enhancement in triphasic CT.

Right renal type 3 heterogeneous angiomyolipoma

Figure S3. Angiomyolipoma enhancement in triphasic CT. AML enhancement curve

Figure S4. Enhancement at arterial and nephrographic phase for each type of AML

Figure S5. Difference in AML enhancement before and under mTORi

Table S1. Patient characteristics

Table S2. Renal characteristics

Table S3. AMLs characteristics

Table S4. Characterization of the 4 types of AML

REFERENCES

- Henske EP, Jóźwiak S, Kingswood JC, et al. Tuberous sclerosis complex. *Nat Rev Dis Primers.* 2016;2:16035. <https://doi.org/10.1038/nrdp.2016.35>
- Pfirmann P, Aupy J, Jambon E, et al. Description of a multidisciplinary model of care in a French cohort of adult patients with tuberous sclerosis complex. *J Med Genet.* 2021;58:25–31. <https://doi.org/10.1136/jmedgenet-2019-106607>
- Park BK. Renal angiomyolipoma: radiologic classification and imaging features according to the amount of fat. *Am J Roentgenol.* 2017;209:826–835. <https://doi.org/10.2214/AJR.17.17973>
- Jinzaki M, Silverman SG, Akita H, et al. Renal angiomyolipoma: a radiological classification and update on recent developments in diagnosis and management. *Abdom Imaging.* 2014;39:588–604. <https://doi.org/10.1007/s00261-014-0083-3>
- Song S, Park BK, Park JJ. New radiologic classification of renal angiomyolipomas. *Eur J Radiol.* 2016;85:1835–1842. <https://doi.org/10.1016/j.ejrad.2016.08.012>

6. Han YM, Kim JK, Roh BS, et al. Renal angiomyolipoma: selective arterial embolization-effectiveness and changes in angiomyogenic components in long-term follow-up. *Radiology*. 1997;204:65–70. <https://doi.org/10.1148/radiology.204.1.9205224>
7. Brakemeier S, Vogt L, Adams L, et al. Treatment effect of mTOR-inhibition on tissue composition of renal angiomyolipomas in tuberous sclerosis complex (TSC). *PLoS One*. 2017;12:e0189132. <https://doi.org/10.1371/journal.pone.0189132>
8. Bissler JJ, Kingswood JC, Radzikowska E, et al. Everolimus for angiomyolipoma associated with tuberous sclerosis complex or sporadic lymphangioleiomyomatosis (EXIST-2): a multicentre, randomised, double-blind, placebo-controlled trial. *Lancet*. 2013;381:817–824. [https://doi.org/10.1016/S0140-6736\(12\)61767-X](https://doi.org/10.1016/S0140-6736(12)61767-X)
9. Rimon U, Duvdevani M, Garniek A, et al. Large renal angiomyolipomas: digital subtraction angiographic grading and presentation with bleeding. *Clin Radiol*. 2006;61:520–526. <https://doi.org/10.1016/j.crad.2006.02.003>